

EP CASE REPORT

Ultra-high density sequential mapping of a focal source of atrial fibrillation

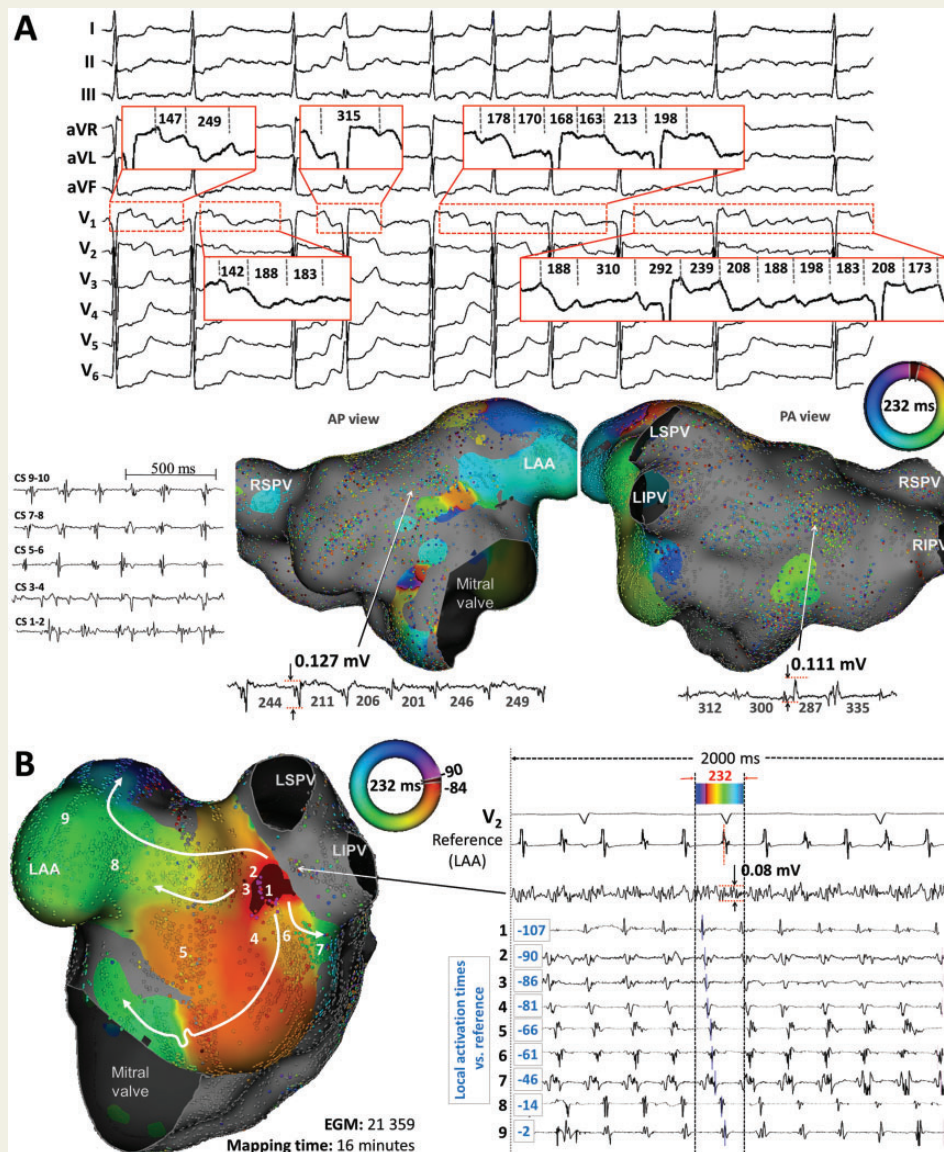
Decebal Gabriel Lațcu*, Sok-Sithikun Bun, and Nadir Saoudi

Cardiology Department, Centre Hospitalier Princesse Grace, Avenue Pasteur, 98000 Monaco (Principality of Monaco)

* Corresponding author. Tel: +377 97 98 97 71; fax: +377 97 98 97 32. E-mail address: dglatcu@yahoo.com

Case report

A 62-year-old male was admitted for redo catheter ablation of highly symptomatic, drug refractory atrial fibrillation (AF) and atrial tachycardia (AT). Previous ablation for persistent AF consisted in circumferential disconnection of the pulmonary veins (PV), ablation of fragmented potentials in the left atrium (LA) and of the cavo-tricuspid isthmus with bidirectional block.



Under general anaesthesia, by right femoral vein access, a decapolar catheter was inserted in the coronary sinus; by transseptal puncture were inserted in the LA: an Orion IntellaMap catheter (Boston Scientific, Cambridge, MA) and a Tacticath Quartz 65 (St Jude Medical). In the beginning of the procedure, the patient was in AT, which was proven to be a macro re-entry in the anterior wall of the LA. During ablation, the rhythm changed to atrial fibrillation (12-lead electrocardiogram (ECG) and coronary sinus (CS)—signals are shown in *Panel A*).

Sequential activation mapping of the AF (see *Figure 1*) was performed by defining as timing reference the left atrial appendage (LAA) electrograms (EGM). Cardiac beats were automatically selected for inclusion in the map based on¹ cycle length (CL) stability (with a 10 ms accepted variability, wider than in case of AT mapping). In contrast to AT,^{2,3} the stable relative timing of two reference EGM was no longer used, neither was the EGM stability, but electrode location stability and respiratory gating were still used. The window of interest (WOI), automatically set by the system at the CL value was centred on the reference EGM. For annotation of the local activation time (LAT) of each acquired bipolar EGM, the system combines unipolar (maximum negative dV/dt) and bipolar (maximum amplitude) EGM. For 'fragmented' or multiple potential EGM, the system takes into account the timing in the surrounding area to select the potential to use for the timing annotation. In case of a lack of statistical coherence between neighbouring points in an area, no colour-code is displayed (the area is left grey—see *Figure 1 Panel A*: antero-posterior-AP- and postero-anterior-PA-views). Scar areas (with bipolar EGM voltage below the scar threshold) are also displayed in grey. The chamber surface geometry is generated using the location of the outer most electrodes, gated to the respiratory and cardiac cycles and updated continuously during mapping. Selection of the surface EGM was based on a 3 mm 'projection distance'.

Activation mapping of AF (21359 EGM, mapping time 16 min) showed incoherent activation timing on wide areas on the anterior and posterior walls of the LA (*Panel A*), as suggested by the grey colour of the activation map; local EGMs with an amplitude above the scar threshold (set to 0.048 mV) excluded scar in his area. In *Panel A* are also shown examples of EGM with variable CL in these areas. Activation mapping also demonstrated a focal source of AF in the middle of the ridge between the left PV and the LAA, from which the LA lateral wall and the LAA were activated centrifugally (*Panel B*, left lateral view of the LA, video). It is not known whether visualization of this focus was facilitated by the proximity with the chosen reference. Local bipolar EGM showed an almost continuous electrical activation at this site (*Panel B*). Radiofrequency delivery at the site of origin stopped AF by transformation into a complex double-loop AT. Subsequent ablation of AT allowed resumption of sinus rhythm. No complication occurred. After a 12-month follow-up, there was no AF recurrence.

Conclusion

Sequential ultra-high density activation mapping of AF using RhythmiaTM may reveal focal sources of AF by allowing visualization of areas of 'organized' activation within the surrounding 'disorganized' regions of fibrillatory conduction.

Conflict of interest: Dr Lațcu and Dr Bun received during the last year speaking honoraria from Boston Scientific.

References

1. Latcu DG, Bun SS, Saoudi N. Combined remote magnetic navigation and ultra-high-density mapping (rhythmia) in slow pathway ablation. *Europace* 2016;**18**:814.
2. Anter E, McElderry TH, Contreras-Valdes FM, Li J, Tung P, Leshem E *et al*. Evaluation of a novel high-resolution mapping technology for ablation of recurrent scar-related atrial tachycardias. *Heart Rhythm* 2016; doi:10.1016/j.hrthm.2016.05.029. [Epub ahead of print].
3. Lațcu DG, Bun SS, Viera F, Delassi T, El Jamili M, Al Amoura A, Saoudi N. Selection of critical isthmus in scar-related atrial tachycardia using a new automated ultrahigh resolution mapping system. *Circ Arrhythm Electrophysiol* 2017;**10** doi:10.1161/CIRCEP.116.004510.